



PATIENT

Sammy Michon

SPECIES

Feline

BREED

Siamese

SEX

Male Neutered

AGE

10 years

WEIGHT

13.9lbs

INTERPRETED BY

Maggie Machen
Lamy, DVM
DACVIM (Cardiology)

PRESENTING CLINICAL SIGNS

History: Recheck echo. History essentially normal cardiac structure and function. Currently, Sammy is presently doing well at home with no problems. Good appetite and his activity remains normal. Needs dental. No murmur ausculted today. BP: 110-120mmHg. *No sedation for study.
-Pertinent previous echo findings (9/2021 MML): Mild PW hypertrophy: 0.61cm. IVSd: 0.48, LA: 1.2cm.

ECHOCARDIOGRAM FINDINGS

2D, m-mode, color flow and Doppler imaging is available.
Left ventricle: The LV diameter is normal with adequate myocardial function. The LV wall is asymmetric with mild posterior wall thickening and a normal septal dimension. There is mild hyperechoic endocardium consistent with fibrosis. The papillary muscles appear hyperechoic and normal in dimension.
Left atrium: The left atrium is normal. No obvious smoke or thrombi seen.
Mitral valve: The mitral valve is normal in structure and mobility. No obvious systolic anterior motion is seen. No MR.
Aortic valve/aorta: The aortic valve is normal in morphology and mobility. Normal aortic outflow velocity; laminar flow. No aortic insufficiency.
Right ventricle: Normal right ventricular diameter and morphology indicating no overt evidence of pulmonary arterial hypertension.
Right atrium: The right atrium is normal in dimension.
Tricuspid valve: The tricuspid valve appears normal with no tricuspid regurgitation.
Pulmonic valve/pulmonary artery: The pulmonic valve is normal in morphology and mobility. No pulmonic insufficiency. Normal RVOT velocity; laminar flow.
Pericardium/other: No obvious pericardial effusion. No obvious pleural effusion noted. Prominent fat pad. No obvious cardiac masses.
Heart rhythm: ECG reveals a sinus rhythm with an average HR of 180bpm.

2-Dimensional Measurements

| | |
|--------------------|------|
| Ao diam (cm) | 1.0 |
| LA diam (cm) | 1.1 |
| LA:Ao (Swe) | 1.1 |
| IVS thickness (cm) | 0.41 |
| LVID diastole (cm) | 1.6 |
| PW thickness (cm) | 0.63 |
| LVID systole (cm) | 0.7 |
| FS (%) | 56 |

Doppler Measurements

| | |
|----------------|------|
| PV Vmax (m/s) | 0.75 |
| AoV Vmax (m/s) | 0.75 |
| MR Vmax (m/s) | NA |
| TR Vmax (m/s) | NA |
| TR PG (mmHg) | NA |

IMAGING PERFORMED BY

Pamela Harrigan,
RDCS

HOSPITAL NAME

Mass Veterinary Services

REFERRING VET

Dr. Masloski

INTERPRETATION OF THE FINDINGS

Compared to the prior study, findings are similar. The posterior wall remains mildly thickened; however, the majority of study is normal. No valve leaks are noted, and the LA remains normal. No additional issues are identified.

INVOICE

26202

DATE

9/6/22

Prognosis remains open given a lack of progression over serial exams.



PATIENT

Sammy Michon

SPECIES

Feline

BREED

Siamese

SEX

Male Neutered

AGE

10 years

WEIGHT

13.9lbs

INTERPRETED BY

Maggie Machen Lamy, DVM
DACVIM (Cardiology)

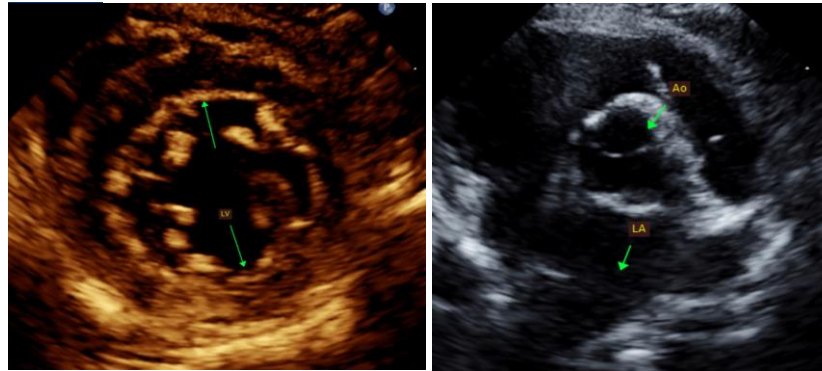
RECOMMENDATIONS

- Given these findings, no medications are indicated.
- Recommend further evaluation for scant pleural effusion.
- No cardiac contraindication for general anesthesia. Should fluid or steroid therapy be indicated in the future, any cat should be monitored for intolerance (changes in RR/RE).
- Monitor at home for signs of cardiac compromise, including respiratory changes and/or signs of a blood clot event (paralysis, neurologic changes).

PLAN

- Recommend recheck echocardiogram in 1 year to assess for any progressive issues or development of disease the pre-existing murmur may mask.

IMAGES



The information and recommendations provided are based on the images presented by the referring veterinarian. No evaluation can be communicated regarding pathology that was not visible in the image/video clips provided.

Thank you for this referral. This report was generated using transcription software, and minor dictation errors may be present. If the clinical or image interpretation does not parallel your findings or if I can be of any further assistance, please contact me.

Maggie Machen Lamy, DVM
Diplomate of the American College of Veterinary Internal Medicine (Cardiology)
info@sonopath.com

Echocardiogram performed by: Pamela Harrigan, RDCS
Pet Animal Ultrasound Service (4paus.com)

IMAGING PERFORMED BY

Pamela Harrigan, RDCS

HOSPITAL NAME

Mass Veterinary Services

REFERRING VET

Dr. Masloski

INVOICE

26202

DATE

9/6/22